

Coccidioidomycosis

Valley fever, also called coccidioidomycosis, is an infection caused by a fungus, *Coccidioides*, found in soil. There are two main types of the fungus that cause valley fever: *Coccidioides immitis* and *Coccidioides posadasii*. Approximately 60% of *Coccidioides* infections are asymptomatic. Symptomatic cases typically present with a mild respiratory syndrome characterized by non-productive cough, shortness of breath, fatigue, night sweats, myalgias and, occasionally, a rash (erythema nodosum or erythema multiforme) between one and three weeks after the individual breathes in the spores. The typical pulmonary infection is self-limiting and clinically indistinguishable from other community-acquired pneumonias.

Immunocompromised patients — e.g., persons with solid organ transplants, human immunodeficiency infection (HIV), lymphoma, or those receiving immunosuppressive therapy such as high-dose steroids or anti-TNF medications — have a higher morbidity and mortality rate than the general population. Some populations — including pregnant women, people living with diabetes, racial groups (Blacks and Filipinos) and immunocompromised persons — are at elevated risk for severe illness.

Coccidioides lives in soil in areas of low rainfall, high summer temperatures and moderate winter temperatures. Unusually wet years lead to large blooms in the soil, while subsequent dry spells kick up the spores and render them airborne. *Coccidioides* is common in the Southwestern United States, including Arizona and Central California, part of Mexico and Central and South America. *Coccidioides immitis* has been found in soils of south-central Washington just across the Columbia River from Oregon. At this time, it is unknown if coccidioidomycosis is established in Oregon soil.

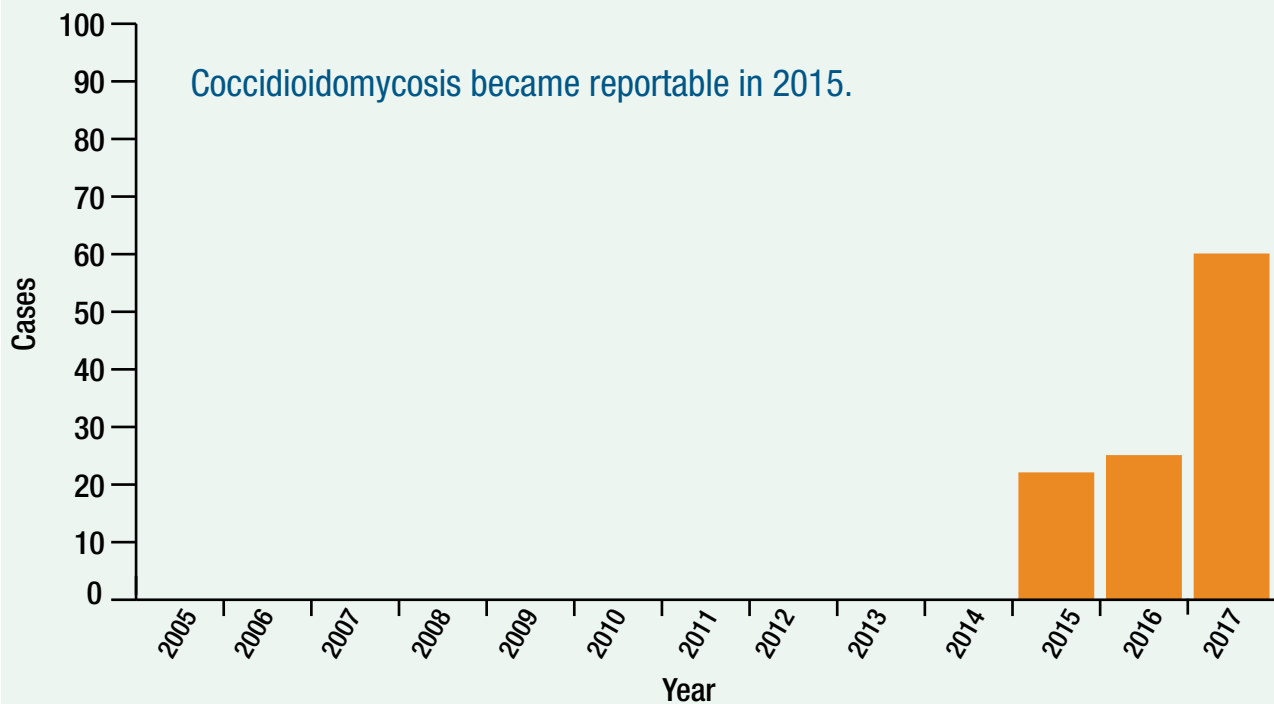
Establishing a diagnosis of coccidioidomycosis may be challenging in humans and animals, and multiple tests including cytology, histopathology, culture and serology may be necessary. A chest X-ray can aid in the diagnosis; pulmonary lesions and hilar lymphadenopathy may be identified in humans and animals with respiratory disease. Isolates from potentially locally acquired cases (human or animal) of coccidioidomycosis should be sent to the Oregon State Public Health Laboratory.

Coccidioidomycosis became a reportable condition in Oregon in 2015. One hundred seven cases have been reported between 2015 and 2017. Sixty-eight cases (64%) of the reports were in males and eighty-one cases (76%) were White. Age range was between 12 and 86 with a mean age of 61 years.

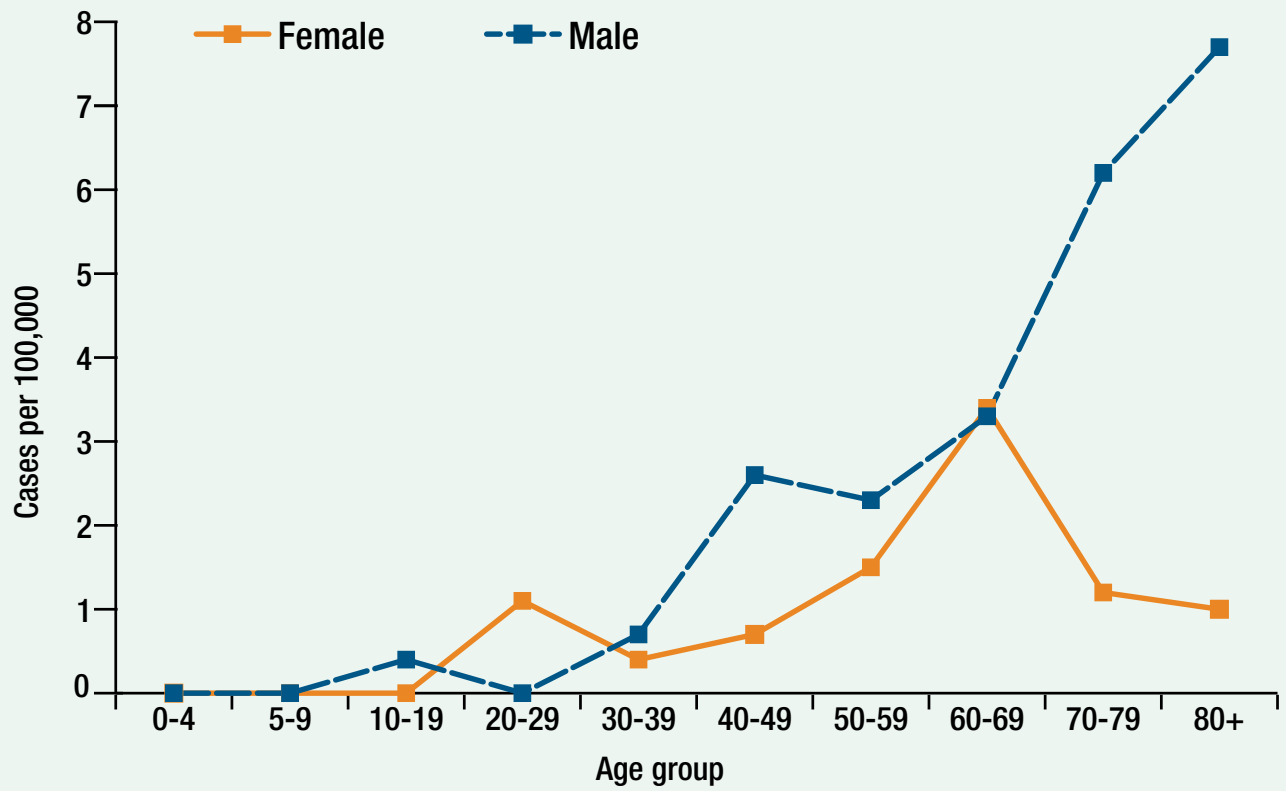
Most infections resolve without treatment, but patients should be monitored to document resolution. Patients with disseminated disease should be treated with antifungal therapy.

Coccidioidomycosis is not usually considered communicable from person to person; however, at least two cases of zoonotic transmission have been documented. In a recent report, a veterinary assistant developed a localized infection with osteomyelitis as the result of a bite from a cat with disseminated coccidioidomycosis. Another zoonotic case apparently acquired coccidioidomycosis by inhaling endospores during the necropsy of a horse with disseminated infection.

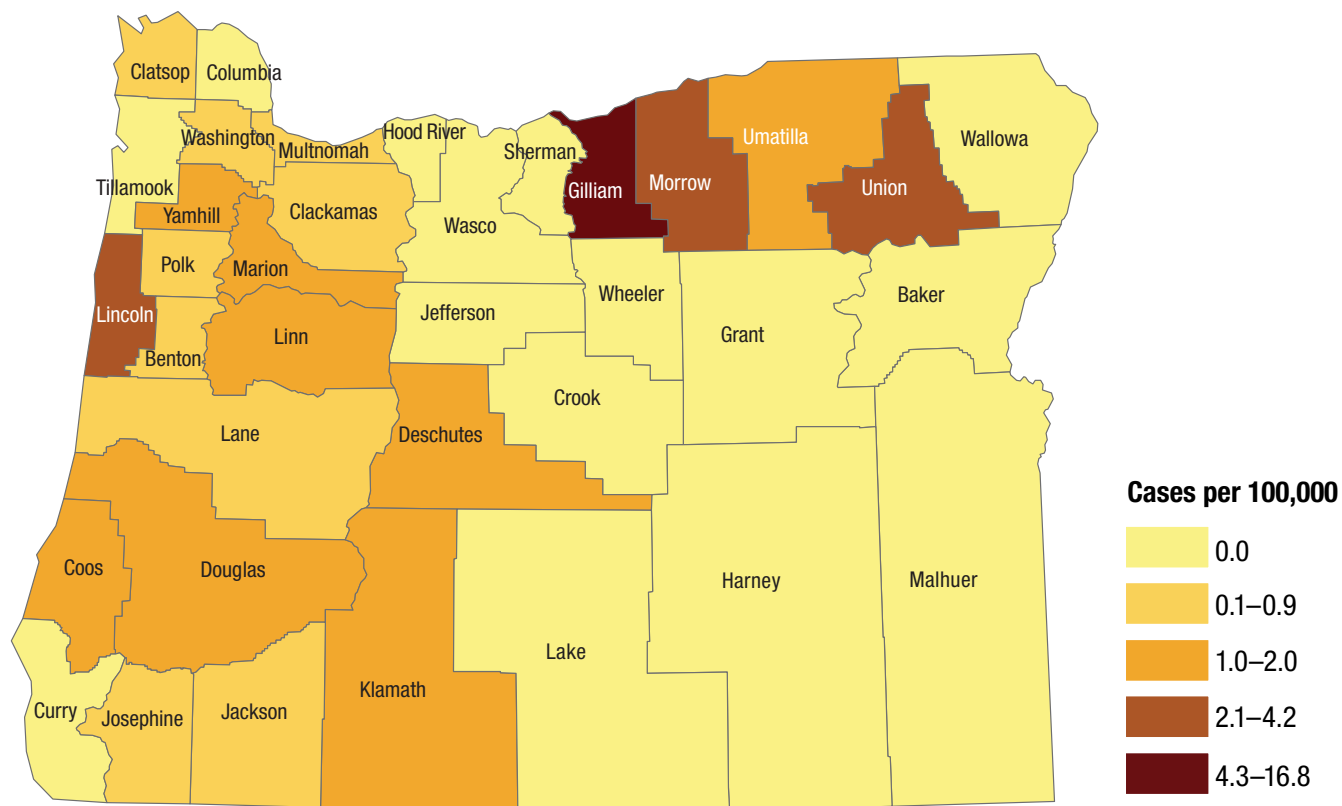
Coccidioidomycosis by year: Oregon, 2005–2017



Coccidioidomycosis by age and sex: Oregon, 2017



Coccidioidomycosis by county of residence: Oregon, 2015–2017



Prevention

- Regrettably, there are no practical methods for preventing exposure to *Coccidioides* in areas where it is common.
- People at higher risk (immunocompromised, pregnant) should avoid breathing in large amounts of dust if they are in these areas. They should also avoid activities that involve close contact with dirt or dust, such as gardening, yard work and digging.
- Patients with coccidioidomycosis can be helped with early diagnosis and treatment with antifungal drugs.