

OREGON PUBLIC HEALTH DIVISION • OREGON HEALTH AUTHORITY

PULMONARY NTM—THE OTHER ACID-FAST BACTERIA

Lady W. is 65. Thin...English émigré...socialite. For two years she's been trying to suppress an unseemly, productive cough with diminishing success. She never smoked. You collect sputum and send for fluorochrome stain. 4+ acid-fast bacilli (AFB). Diagnosis made! and the full weight of the tubercular-industrial complex descends upon her. Airborne isolation. Four-drug therapy. Contact investigation...

NOT TB

But not so fast. This is about those other acid fast bacteria.* We call them nontuberculous mycobacteria, NTM for short. They cause 2 to 3 times more cases of symptomatic pulmonary illness in Oregon every year than their notorious siblings of the *Mycobacterium tuberculosis* Complex. Lady Windermere's case illustrates that it can be difficult to distinguish NTM disease from tuberculosis, sometimes leading to inappropriate initial treatment and unnecessary airborne isolation or contact investigations.

Happily, after noting acid-fast bacteria in the sputum, the crack microbiologist subjected Lady W.'s sputum to a nucleic acid amplification test to rule out *M. tuberculosis*, leading rapidly to recognition of unspecified NTM-related disease, sparing her isolation and mistreatment (and the taxpayer some dough). Subsequent computed tomography revealed right middle lobe bronchiectasis with scattered "tree-and-bud" inflammation, and micronodular infiltrates in the right middle lobe and both lower lobes of the lungs. *Mycobacterium avium-intracellulare* eventually grew from two of her sputum samples. After speciation and susceptibility testing, her physician began daily treatment with azithromycin, rifampin and ethambutol.

Nontuberculous mycobacteria reside all around us in all manner of water and soil; why some people become ill while most don't is one of

life's lesser mysteries. NTM-related illness is not transmissible from human to human by droplets or other airborne modes of travel, and we don't yet know how to prevent disease.

NTM cause both pulmonary and extrapulmonary disease. This issue is devoted to pulmonary NTM disease. More than 90% of symptomatic pulmonary NTM infection is caused by species of the *M. avium* Complex or the *M. abscessus* Complex (Table 1).¹

Table 1. Mycobacteria causing human disease^{2,3}

- ***M. tuberculosis* Complex**
M. tuberculosis, bovis, africanum, microti, canetti
- *M. leprae*

Rapidly growing NTM

- ***M. fortuitum* Complex**
M. fortuitum, peregrinum, porcinum
- ***M. chelonae***
- ***M. abscessus* Complex**
M. abscessus, bolletii
- ***M. smegmatis***
- ***M. mucogenicum***

Slowly growing NTM

- **Photochromogens**
M. kansasii, marinum
- **Scotochromogens**
M. goodii, scrofulaceum
- **Nonchromogens**
M. asiaticum, avium Complex (*avium, intracellulare*), *haemophilum, malmoense, terrae* Complex, *simiae, szulgai, ulcerans, xenopi*

Pulmonary NTM disease is often chronic and debilitating and primarily affects people aged ≥45 years; incidence increases with age. Other risk factors include chronic obstructive pulmonary disease (COPD), bronchiectasis, and cystic fibrosis. (Many people with cystic fibrosis are <45 years of age.) Commonly, patients complain of chronic cough, wheezing, dyspnea, fatigue, night sweats, weight loss, depression, social anxiety, and hemoptysis.¹ More than 16,000 NTM-

associated hospitalizations were identified in national hospital discharge data over a 7-year period from 1998 through 2005, and a review of Medicare claims data led to an estimate of 50,000 prevalent U.S. cases in patients aged ≥65 years from 1997–2007.^{2,3}

Two distinct clinical presentations are commonly seen. In one the patient is a middle-aged, male smoker with COPD with a rapidly progressing apical cavity or fibronodular disease. In the other, the patient is typically a slender, older female ("Lady Windermere"), though as many as two-fifths are male.^{4,5} She often has interstitial nodular infiltrate, bronchiectasis in the right middle lobe or lingula, or bronchiolitis ("tree in bud") on high resolution CT scan. Sometimes the 'Lady W's' have thoracic abnormalities, including scoliosis and pectus deformities.⁶ Nodular bronchiectatic disease usually progresses slowly over many years, but requires regular monitoring for worsening symptoms or radiographic disease progression that indicates treatment should be initiated. Which comes first isn't clearly known, but infection and associated inflammation probably drives progression of airway damage and dilatation (bronchiectasis).

DX

The American Thoracic Society provides diagnostic criteria for pulmonary NTM disease (Table 2, *verso*).¹ Often, the clinician needs to rule out tuberculosis. Nucleic acid tests (NAATs) for *M. tuberculosis* complex, whether AFB are visible in sputum or not, can rule TB in or out. In a patient like Lady W. with visible AFB, a negative NAAT presumptively indicates NTM-related illness and spares her the isolation and presumptive TB treatment that often would have ensued in the olden days.

Oregon is the only state in which any form of NTM infection is reportable — and only non-respiratory

* Yes, we're ignoring Nocardia.



If you need this material in an alternate format, call us at 971-673-1111.

The **CD Summary** (ISSN 0744-7035) is published fortnightly free of charge and is now delivered by e-mail. To sign-up, zap your request to cd.summary@state.or.us. Please include your full name and mailing address (not just your e-mail address)

EARN FREE CME CREDIT. CME credits are available.. See http://healthoregon.org/cd_summary for more information.

Table 2. Diagnostic criteria for non-tuberculous mycobacterial pulmonary disease

• **Clinical**

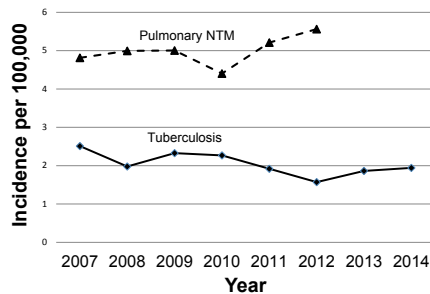
Pulmonary symptoms, nodular or vacitary opacities, or high resolution computed tomography (CT scan that shows multifocal bronchiectasis with multiple small nodules) AND appropriate exclusion of other diagnoses

• **Microbiologic**

Positive NTM culture results from at least two separate expectorated sputum samples or one broncoalveolar lavage

NTM is reportable here. Nevertheless, Oregon has accepted voluntary reports since 2007. As Figure 1 illustrates, pulmonary NTM disease is at least twice as common as active TB. Incidence increases with age, and overall, women are at higher risk than men (Figure 2).

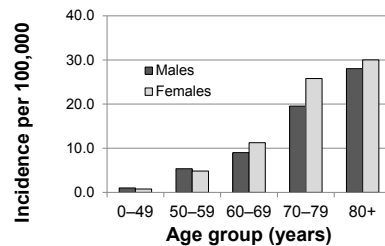
Figure 1. Pulmonary NTM and tuberculosis disease, Oregon, 2007–2014



RX

Few clinical trial data are available to inform treatment of pulmonary NTM; current guidelines are based on expert opinion. The decision to treat should be based on disease burden, symptoms, and tolerance of therapy. Patients with nodular bronchiectatic or mild disease can be monitored without antibiotics. Even when treatment seems appropriate, some experts advise waiting for speciation and susceptibility studies. When undertaken, the recommended antibiotic regimen is 18–24 months of

Figure 2. Pulmonary NTM disease by age and sex, Oregon, 2007–2012



a three-drug combination including a macrolide (either clarithromycin or azithromycin), rifampin, and ethambutol, either in daily or intermittent fashion. Sputum cultures should be obtained every 3 months and therapy discontinued only when sputum cultures have been negative for 12 months. Unfortunately, pulmonary NTM frequently recurs, necessitating repeated treatment, often with alternate antibiotics because of resistance developed during the initial treatment. Lobectomy or resection of cavities is occasionally necessary.

CONCLUSION

Some kind of summative conclusion is usually a nice way to end, but the muse is at home sick. We leave you with a quote from Oscar Wilde, Lady Windermere's creator.

I was working on the proof of one of my [CD Summaries] all the morning, and took out a comma. In the afternoon I put it back again.

FOR MORE INFORMATION

- Differentiating pulmonary NTM from TB see: Kendall BA, Varley CD, Donseok CP, Cassidy M, Hedberg K, Ware MA and Winthrop K. Distinguishing tuberculosis from nontuberculous mycobacteria lung disease, Oregon, U.S.A., Emerging Infectious Diseases 2011;17 See: http://wwwnc.cdc.gov/eid/article/17/3/10-1164_article
- Reportable non-pulmonary NTM in Oregon, see <https://public.health.oregon.gov/DiseasesConditions/DiseasesAZ/Pages/disease.aspx?did=124>
- CDC. Other *Mycobacterium* Species. See: http://www.cdc.gov/mcvod/divisions/dfbmd/diseases/nontb_mycobacterium/technical.html

REFERENCES

1. Griffith DE, Aksamit T, Brown-Elliott BA, et al. An official ATS/IDSA statement: Diagnosis, treatment, and prevention of nontuberculous mycobacterial diseases. American journal of respiratory and critical care medicine 2007;175:367–416.
2. Billinger ME, Olivier KN, Viboud C, et al. Nontuberculous mycobacteria-associated lung disease in hospitalized persons, United States, 1998–2005. Emerging infectious diseases 2009;15:1562–9.
3. Adjemian J, Olivier KN, Seitz AE, Holland SM, Prevots DR. Prevalence of nontuberculous mycobacterial lung disease in U.S. Medicare beneficiaries. American journal of respiratory and critical care medicine 2012;185:881–6.
4. Reich JM, Johnson RE. *Mycobacterium avium* complex pulmonary disease presenting as an isolated lingular or middle lobe pattern. The Lady Windermere syndrome. Chest 1992;101:1605–9.
5. Henkle E HK, Schafer S, Novosad S, Winthrop K. Population-based incidence of pulmonary nontuberculous mycobacterial disease in Oregon 2007–2012. Annals ATS 2015;12:642–7.
6. Iseman MD, Buschman DL, Ackerson LM. *Pectus excavatum* and scoliosis. Thoracic anomalies associated with pulmonary disease caused by *Mycobacterium avium* complex. The American review of respiratory disease 1991;144:914–6.